

Palatoschisis in the dog: developmental mechanisms and etiology

Palatoschisis bij de hond: ontwikkelingsmechanismen en etiologie

^{1,2}F. Van den Berghe, ¹P. Cornillie, ³L. Stegen, ³B. Van Goethem, ¹P. Simoens

¹Department of Morphology

²Department of Reproduction, Obstetrics and Herd Health

³Department of Medicine and Clinical Biology of Small Animals

Faculty of Veterinary Medicine, Ghent University, Salisburylaan 133, B- 9820 Merelbeke, Belgium

Femke.vandenbergh@yaho.com

ABSTRACT

Palatoschisis is a frequently occurring birth defect in man and domestic animals. It is caused by a failure of the elevation, apposition or fusion of the lateral palatine processes, resulting in the persistence of a slit-like opening between the oral and nasal cavities. Due to swallowing difficulties, this condition eventually leads to severe malnutrition and life-threatening aspiration pneumonia unless adequate treatment is provided. The formation of the palate is the result of a sequence of well-regulated steps. Palatoschisis can result from any interference with local cell proliferation, differentiation and apoptosis, the aberrant production of mucopolysaccharides or interference with the active extension of the neck. It results from a single or combined action of genetic, mechanical and/or environmental teratogenic factors. The complex etiology of a cleft palate, its potential hereditary characteristics and possible association with other congenital defects should be carefully considered prior to any corrective therapy.

SAMENVATTING

Palatoschisis of een gespleten gehemelte is een aangeboren afwijking die zowel bij de mens als de huisdieren frequent wordt waargenomen. De aandoening wordt veroorzaakt door een gebrek in de elevatie, appositie of fusie van de laterale gehemelteplooiën tijdens de embryonale ontwikkeling, waardoor een spleetvormige verbinding tussen de mondholte en neusholte aanwezig blijft. Zonder adequate behandeling veroorzaken de bijhorende slikproblemen ernstige ondervoeding en zelfs levensbedreigende aspiratiepneumonie. De vorming van het gehemelte omvat een complex gereguleerde opeenvolging van verschillende stappen. Palatoschisis kan ontstaan uit eender welke verstoring van lokale celproliferatie, -differentiatie en apoptose, een afwijkende productie van mucopolysacchariden of een belemmering van het actief strekken van de nek. Zowel een genetische, mechanische of teratogene omgevingsfactor of een combinatie daarvan kan aan de basis liggen van een dergelijke afwijking. De complexe etiologie van een gespleten gehemelte, de mogelijke erfelijke basis en de mogelijke associatie ervan met andere congenitale afwijkingen dienen in rekening te worden gebracht indien een therapie wordt overwogen.

INTRODUCTION

Palatoschisis or cleft palate is one of the more commonly described congenital defects in man and domestic animals. In humans, its prevalence ranges from 0.05 to 0.3% of all pregnancies, depending on population, sex and geographical location (Thornton *et al.*, 1996), while in domestic animals, an average of 0.6 cases per 1000 births has been reported (Noden and de Lahunta, 1985). In dogs, the occurrence of cleft palate is more frequently observed in beagles, cocker spaniels, dachshunds, Labrador retrievers, schnauzers and Shetland sheepdogs. Brachycephalic breeds can have up to a 30% risk factor (Ingwersen, 2005).

The presence of a fully developed palate is a typical feature of mammals (Bulleit and Zimmerman,

1985). The only non-mammalian species in which the oral and nasal cavities are entirely separated from each other through the palate belong to the family of the crocodylians. In these species, the palate permits breathing while the mouth is submerged under water (Ferguson, 1981), whereas the presence of a correctly developed palate in mammals is essentially to allow the proper swallowing of food and liquids, and to enable the suckling of milk by the newborn (Nelson, 2003).

In an affected individual, alimentary nasal discharge, due to the inability to generate suction and the presence of an open connection between the oral and nasal cavities, is one of the first symptoms to be noticed. Food entering the nasal cavity through the defect also causes irritation and inflammation of the nasal

mucosa, resulting in sneezing and nasal discharge (Nelson, 2003). Swallowing difficulties, expressed by coughing and regurgitation, eventually lead to severe malnutrition and life-threatening aspiration pneumonia (Ishikawa *et al.*, 1994).

Medical intervention in such cases is therefore indispensable for the survival of the patient and to guarantee a reasonable quality of life (Griffiths and Sullivan, 2001; Nelson, 2003). Whereas in human medicine numerous therapeutic possibilities have been developed to compensate for or correct palatoschisis, pets suffering from a cleft palate are usually euthanized for welfare, financial and/or practical reasons. In the past, surgical correction of a cleft palate in animals has been associated with a high failure rate (Howard *et al.*, 1974). However, newer techniques are improving the success rates in dogs (Ingwersen, 2005).

Still, the decision whether or not to perform surgery should be carefully considered, taking all practical, technical, financial and ethical issues into account. A thorough knowledge of the normal development and conformation of the palate and a broad understanding of the etiology and pathogenesis of the different types of cleft palate are indispensable in this regard. This article is therefore intended to provide a brief review of the developmental anatomy of the palate and the pathomechanisms involved in the schistopalatine syndrome, with special reference to the dog.

EMBRYONIC DEVELOPMENT OF THE PALATE

Morphogenesis of the palate

In the early embryo, the primitive mouth or stomodeum is covered by the frontonasal prominence, flanked by the maxillary processes of the first visceral arches and lined ventrally by the mandibular processes, which fuse with each other to form the lower jaw (Figure 1).

At the rostral end of the frontonasal prominence, just dorsal to the stomodeum, two nasal placodes invaginate to form the nasal pits or nasal sacs. Subsequently, the ventral walls of the expanding nasal sacs fuse with the roof of the stomodeum, after which these so-called oronasal membranes degenerate, hereby creating a single oronasal cavity. The dorsal half of the oronasal cavity is subdivided by a primitive nasal septum, while its ventral half is mainly occupied by the voluminous tongue. The dorsal surface of the tongue is directly apposed to the ventral aspect of the primitive nasal septum, which is therefore often referred to as the primitive palate (Noden and de Lahunta, 1985).

Externally, each nasal pit is circumscribed by two swellings: a lateral and a medial nasal prominence. On either side, the lateral nasal prominence is soon reached by the rostrally expanding maxillary process. Each maxillary process subsequently bridges the nostril ventrally and finally fuses with the ipsilateral medial nasal prominence. Both medial nasal prominences expand markedly and eventually contact each other in the rostral midline (McGeady *et al.*, 2006).

The development and fusion of all these components is essential for the correct formation of the nose, upper lips and upper jaws. After the medial nasal prominences have fused with each other, they form the median palatine process, which extends caudally as a shelf-like projection into the oronasal cavity. This structure, along with the rostroventral part of the nasal septum, creates a clear separation between the stomodeum and the two nasal cavities in the rostralmost part of the oronasal cavity and is therefore referred to as the primary palate. It persists as a small, triangular structure that corresponds to the rostralmost part of the definitive palate, in which the incisive bones develop (Noden and de Lahunta, 1985; Sinowatz, 1991).

The development of the secondary or actual palate starts with the development of the lateral palatine

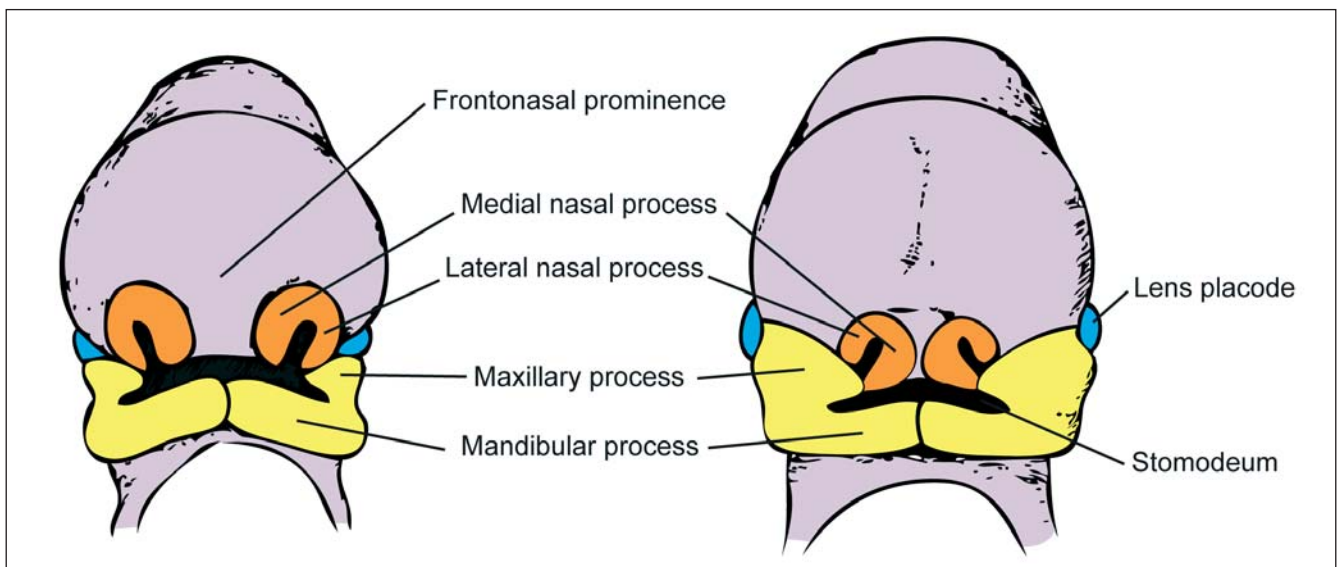


Figure 1. Rostral view of the developing face in the mammalian embryo (schematic drawing). Left: Early stage after formation of the nasal pits. Right: Later stage after fusion of the maxillary processes with the ipsilateral medial nasal processes.

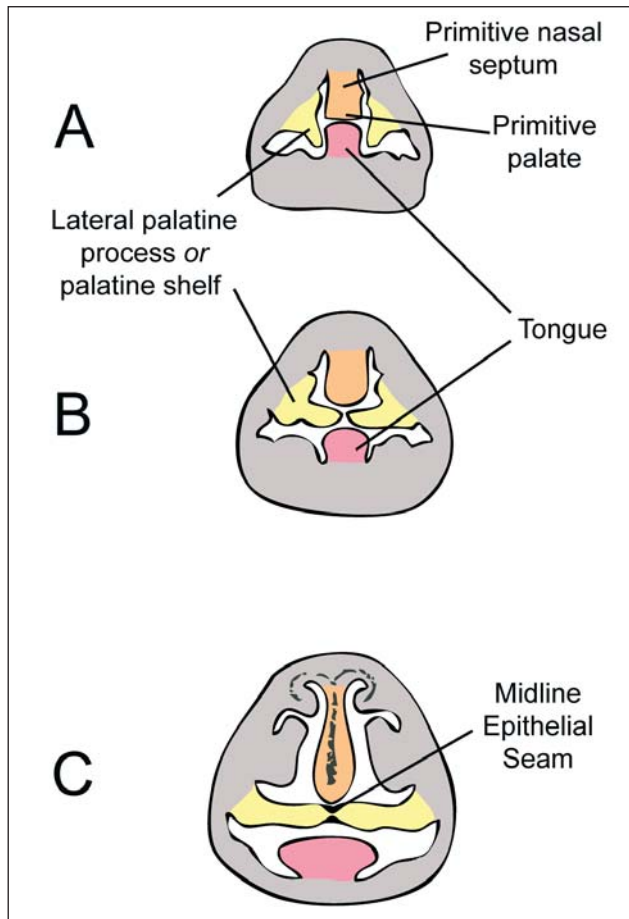


Figure 2. Transverse sections through the oronasal cavity of an embryo at 4 subsequent stages of palatogenesis (schematic drawing). A: Original position of the palatal shelves lateral to the tongue, B: Elevation of the palatal shelves, C: Fusion of the palatal shelves and formation of the Midline Epithelial Seam, D: End stage of palatogenesis.

processes, often referred to as the palatal shelves, emerging from the medial aspects of the maxillary processes (Figure 2). Both lateral palatine processes initially grow in a ventromedial direction, thereby occupying the space between the lateral surface of the tongue and the mandibular processes. At a specific time, the palatal shelves elevate to a horizontal position dorsal to the tongue, so that their free margins become directly apposed. Almost immediately thereafter, both palatal shelves fuse with each other and with the nasal septum, resulting in the definitive separation of the oral cavity from the nasal cavity and the partitioning of the nasal cavity into two separate chambers (Ferguson, 1988; Thornton *et al.*, 1996; Kang and Svoboda, 2005).

Rostrally, the secondary palate connects with the primary palate. At their site of fusion, the incisive papilla, bilaterally flanked by the incisive ducts, develops (Sinowatz, 1991). The mesenchyme in the rostral two-thirds of this definitive palate undergoes intramembranous ossification, forming the hard palate (Noden and de Lahunta, 1985), while mesenchyme in the caudal third expands and develops a muscular core

to form the soft palate (Sinowatz, 1991). The entire process of palatogenesis in the dog takes place between the 25th and 28th-33rd day of development (Noden and de Lahunta, 1985; Nelson, 2003).

Mechanisms of palatal shelf elevation

The actual process of palatal shelf elevation and fusion takes only a few minutes to a few hours (Dudas *et al.*, 2006) and is controlled by complex regulatory mechanisms. The forces that drive the palatal shelf elevation are primarily intrinsic factors of the composing tissues. A progressive accumulation and hydration of hyaluronic acid induces swelling of the mesenchymal stroma and a decrease in mesenchyme density (Morris-Wiman and Brinkley, 1993). The orientation and direction of the resulting expansion of the palatal shelves is controlled by other components of the extracellular matrix such as collagen type I (Foreman *et al.*, 1991; Mansell *et al.*, 2000), but also by the covering epithelium and its underlying basement membrane (Morris-Wiman and Brinkley, 1993).

Extrinsic factors also play a major role in the re-orientation of the palatal shelves. These consist of active and passive movement of the tongue (e.g. by traction on the genioglossus muscles due to the elongation of the lower jaw) and non-palatal muscular contractions such as opening of the mouth, sudden hyperextension of the neck and swallowing (Brinkley *et al.*, 1978). The final goal of these forces is to depress or retract the tongue so that the space between the two palatal shelves is cleared, allowing the palatine processes to reorient (Fraser, 1967; Chou *et al.*, 2004).

Mechanisms of palatal shelf fusion

The size of the lateral palatine processes is such that as soon as they assume a horizontal position, their margins are apposed (Noden and de Lahunta, 1985). Their medial edges are covered with a bilayered epithelium consisting of a basal cuboidal epithelial layer commonly referred to as the Medial Edge Epithelium (MEE) and an outer peridermal layer composed of flattened cells. During a process called peridermal peeling, the periderm on the edge of the palatal shelves is dissolved through apoptosis or migration of the peridermal cells towards the oral or nasal surface (Bittencourt and Bolognese, 2000; Dudas *et al.*, 2006). The underlying MEE is exposed and acquires the competence to interact with the MEE of the contralateral palatine shelf (Dudas *et al.*, 2006).

Disappearance of the midline epithelial seam

Following adhesion of the lateral palatine processes to each other and to the primitive nasal septum, the epithelium that once covered the apical surfaces of these three processes becomes trapped within the junction site. These cells arrange themselves into the Midline Epithelial Seam (MES), a double wedge-

shaped epithelial cell mass that needs to disappear to allow mesenchymal confluence and completion of the process of palatal fusion (Jin and Ding, 2006). The bases of the two wedges abut on the oral and nasal surfaces of the palate, respectively, while their edges are in contact with one another in the palatal center.

Three different mechanisms are theorized to be responsible for the disintegration of the MES. Cuervo *et al.* (2002) have shown that apoptosis is overabundant in the MES and that this programmed cell death is necessary for the normal closure of the palate. On the other hand, Griffith and Hay (1992) experimentally confirmed the observation by Ferguson (1988) that more than 50% of the MES cells undergo epithelial-mesenchymal transdifferentiation and transform into fibroblasts. As a third option, Carette and Ferguson (1992) proposed that the cells of the MES migrate towards the oral and nasal cavities to incorporate themselves into the surface epithelium. Most probably, the disintegration of the MES is directed by a combination of all three mechanisms (Martinez-Alvarez *et al.*, 2000).

TYPES OF PALATOSCHISIS

A congenital palatal fissure is the result of the non-closure either of the primary or of the secondary palate, or of a combination of the two (Warzee *et al.*, 2001). In cases in which the primary palate is involved, the anomaly is always associated with defects of the upper lip (cleft lip, schistocheilia) and upper jaw (gnathoschisis), resulting in severe facial malformation. A fuller description and further classification of this group of defects, however, falls beyond the scope of this paper.

The term palatoschisis or cleft palate is typically reserved for defects of the secondary palate only. Within this group, a further distinction is made between complete clefts, in which both the hard and the soft palate are affected (Figure 3), and incomplete clefts, which usually involve only the soft palate (Sinibaldi, 1979; Thornton *et al.*, 1996).



Figure 3. Four neonatal pups from two litters from the same breeder displaying palatoschisis at the level of the secondary palate.

Typically, the palatal fissure is present in the midline as a more or less large gap connecting the oral and the nasal cavities, and exposing the nasal septum in the oral cavity. In cases where only one of the two lateral palatine processes manages to fuse with the primitive nasal septum, a cleft palate will be unilaterally present. Bilateral clefts can also occur at the level of the soft palate. In these cases, a central piece of tissue, typically containing the palatine muscles, is present between the two fissures (Sager and Nefen, 1998; Griffiths and Sullivan, 2001).

A special type of palatoschisis is the occult, submucous cleft palate in which incompletely fused palatine bones are covered by a continuous mucosa (Okano *et al.*, 2006).

Most commonly, palatoschisis occurs as a solitary entity. However, in approximately 8% of the affected dogs, a cleft palate or cleft lip is associated with developmental anomalies affecting other organ systems (Ingwersen, 2005), most often the skeletal system (Nelson, 2003).

ETIOLOGY AND PATHOMECHANISMS

Genetic causes and breed predisposition

In human medicine, 25-30% of the cases of palatoschisis can be attributed either partially or completely to a certain genetic component (Leite *et al.*, 2002). At least 20 different genes in mice and man are essential for normal palatogenesis (Kang and Svoboda, 2005; Okano *et al.*, 2006). Any disruption of the action of these genes during the critical period of palatal development results in palatoschisis. In such cases, this defect is mostly combined with other structural or functional anomalies as a part of a specific syndrome (Murray and Schutte, 2004).

In dogs, little or no specific data on the genetic background of palatoschisis can be found in the literature (Kemp *et al.*, 2009), but the typical aforementioned breed predispositions strongly suggest a hereditary basis for this anomaly (Elwood and Colquhoun, 1997). Moreover, incidence in the offspring of two affected animals can rise to as high as 41.7% (Nelson, 2003). Although an autosomal recessive inheritance of palatoschisis has been suggested (Richtsmeier *et al.*, 1994), the defect is most likely a complex trait caused by multiple genetic and environmental factors (Murray and Schutte, 2004). Brachycephalic breeds, in particular, are highly susceptible to any additional disruptive factor, as the growth of the palatal shelves towards each other is already compromised by the typical broad head and the greater distance that therefore needs to be bridged by the two palatal shelves (Warzee *et al.*, 2001).

Factors affecting tongue movement

In the early phases of palatogenesis, the tongue is situated between the two palatal shelves. It has to move downwards to allow palatal shelf elevation and

apposition. The retraction of the tongue is mainly accomplished by a hyperextension of the neck. Any disturbance of this mechanism will result in a cleft palate. This failure can be due to hyperflexion of the embryo caused by oligohydramnios (Fraser, 1967), or it can occur as a result of cervical malformations (Ferguson, 1988). Additionally, certain teratogens affecting muscle contractions, such as anabasine, an alkaloid related to nicotine, can prevent retraction of the tongue and consequentially cause palatoschisis (Weinzweig *et al.*, 2008).

Factors affecting palatal shelf growth and elevation

The growth and reorientation of the palatal shelves relies mainly on sufficient production and accumulation of mucopolysaccharides (Morris-Wiman and Brinkley, 1993). Certain drugs, such as corticosteroids and non-steroidal anti-inflammatory drugs, interfere with the synthesis of these mucopolysaccharides and with the proliferation of mesenchymal cells, resulting in smaller palatal shelves that fail to fuse (Fraser, 1967; Yoneda and Pratt, 1982; Lu *et al.*, 2008). Particularly in the dog, the administration of acetylsalicylic acid (Aspirin, Bayer) between day 23 and day 30 after conception results in multiple congenital malformations, including palatoschisis in the offspring (Robertson *et al.*, 1979).

The incidence of corticosteroid-induced palatoschisis can be reduced by the administration of pyroxidine (Vit. B₆) or cobalamin (Vit. B₁₂) (Yoneda and Pratt, 1982; Lu *et al.*, 2008).

Uncontrolled diabetes mellitus in the dam is also a risk factor for the development of a cleft palate. High levels of plasma glucose interfere with the function of arachidonic acid, which plays a role in palatal shelf elevation (Goldman *et al.*, 1985).

Factors affecting the Medial Edge Epithelium

Apart from their interference with palatal shelf growth and elevation, glucocorticoids also have an effect on the proliferation and/or apoptosis of the Medial Edge Epithelial cells. It has been shown that dexamethasone induces a thickening of the MEE, and that the MEE does not disappear when the two palatal shelves ought to fuse (Lu *et al.*, 2008).

Environmental contaminants such as dioxins, in particular 2,3,7,8-tetrachlorodibenzo-*p*-dioxine (TCDD), can also disrupt the proliferation and differentiation of the MEE, resulting in a cleft palate (Lu *et al.*, 2008).

Role of folic acid

Folic acid (Vit. B₁₁ or Vit. B₉) is the synthetic and stable form of the naturally occurring folates (Tapiara *et al.*, 2007). Folate supplementation in women in the periconceptional period has been shown to substantially reduce the risk of neural tube defects such as spina bifida, and, although hard evidence is lacking, it has also been suggested that it prevents orofacial clefts

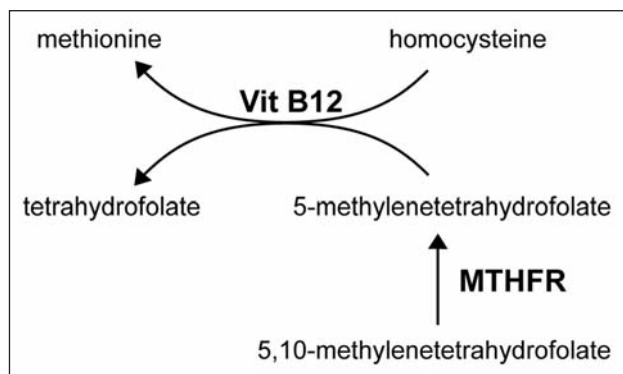


Figure 4. Role of vitamin B₁₂ and the enzyme methylenetetrahydrofolate reductase (MTHFR) in the folate metabolism.

(Johnson and Little, 2008). In dogs, the incidence of palatoschisis was reduced by 76% after supplementation of folic acid at 5 mg/day in a population of Boston terriers (Elwood and Colquhoun, 1997).

Folates play a major role in DNA synthesis and cell proliferation. Folate deficiencies can lead to megaloblastosis and cell death, particularly in highly proliferative tissues (Antony, 2007). Disturbances of the folate metabolism, for example due to defects of the methylenetetrahydrofolate reductase (MTHFR) or mediated by antiepileptic drugs such as phenytoin, lead to higher levels of circulating homocysteine (Figure 4). Hyperhomocysteinemia can disturb palatogenesis by interfering with the normal methylation of certain important developmental genes (Krapels *et al.*, 2006). It is also responsible for an increase in oxidative stress, resulting in more cell damage and apoptosis (Knott *et al.*, 2003). Finally, the binding of homocysteine to the folate receptors on the placenta can provoke a maternal immune response, resulting in the destruction of the folate receptors and a decrease in folate transport to the fetus (Tapiara *et al.*, 2007).

General teratogens

Apart from causing other major congenital defects, antimetabolites and cytostatic drugs can also induce the formation of a cleft palate (Verhaert, 2007). Additionally, vitamin A, and in particular its metabolite retinoic acid, is a well known teratogen that is able to disturb many developmental processes, including palatogenesis. An excess of retinoic acid results in saturation or inactivation of several important intracellular or membrane-bound receptors, leading to cellular damage or reduction in retinoic-acid mediated cell signaling (Krapels *et al.* 2006), ultimately resulting in hypoplasia of the palatal shelves with abnormal cartilage and bone formation (Fraser, 1967).

The offspring of dams with aberrant cholesterol metabolism show multiple congenital malformations, including cleft palate. Cholesterol is essential for the proper processing of the Sonic Hedgehog protein, a vital element in many embryonic processes (Krapels, 2004; Murray and Schutte, 2004; Young *et al.*, 2000).

Finally, certain viral infections have also been as-

sociated with the formation of a cleft palate, mainly as a result of a postclosure reopening at late fetal stages or in the newborn (Fraser, 1967). This situation can correspond with submucous palatal clefts (Dudas *et al.*, 2006).

DISCUSSION

The complex developmental pattern of palatogenesis, which spans a relatively long period during organogenesis, relies on the correct action and interaction of many different types of embryonic tissues and processes. For this reason, the formation of the palate is highly susceptible to the disruptive effects of a broad range of genetic and environmental teratogenic factors, which explains the frequent occurrence of palatoschisis both in man and domestic animals (Noden and de Lahunta, 1985). As a further consequence, in individual cases of cleft palate, the identification of the exact etiological agents is nearly always an impossible task (Thornton *et al.*, 1996).

Because many of the disruptive genetic or environmental factors involved in palatoschisis do not specifically act on the process of palatogenesis, but also disturb the development and function of multiple other structures, the presence of a cleft palate might be part of a syndrome (Murray and Schutte, 2004; McGeady *et al.*, 2006). Concomitant congenital defects in other organs should therefore always be taken into account when considering corrective therapy in patients with cleft palate.

On the other hand, as the series of events involved in palatogenesis happens later in embryonic development than most other morphogenic events do, it is as such possible that teratogenic agents interfere solely with the formation of the palate, without affecting other organ systems (Noden and de Lahunta, 1985). In such non-syndromic cases, corrective therapy, which will be discussed in the sequel paper, might be a favorable option to prolong the life expectancy and assure an adequate quality of life, although breeding with the animal should still be discouraged due to the potential hereditary nature of the anomaly, as it has been shown that cross-breeding with two affected dogs raises the incidence in the descendants to 41.7% (Nelson, 2003). Because of the complex etiology with potential involvement of mechanical or environmental factors, further breeding with the parents of the affected animal is not immediately discouraged, though it has to be carefully considered, evaluating the possibility of a hereditary cause in each specific case.

REFERENCES

Antony A.C. (2007). In utero physiology: role of folic acid in nutrient delivery and fetal development. *The American Journal of Clinical Nutrition* 85, 598-603.
 Bittencourt M.A.V., Bolognese A.M. (2000). Epithelial alterations of secondary palate formation. *Brazilian Dental Journal* 11, 117-126.
 Brinkley L., Basehoar G., Avery J. (1978). Effects of craniofacial structures on mouse palatal closure in vitro. *Journal of Dental Research* 57, 402-411.

Bulleit R.F., Zimmerman E.F. (1985). The influence of the epithelium on palate shelf reorientation. *Journal of Embryology and Experimental Morphology* 88, 265-279.
 Carette M.J.M., Ferguson M.W.J. (1992). The fate of medial edge epithelial cells during palatal fusion in vitro: an analysis by Dil labelling and confocal microscopy. *Development* 114, 379-388.
 Chou M., Kosazuma T., Takigawa T., Yamada S., Takahara S., Shiota K. (2004). Palatal shelf movement during palatogenesis: a fate map of the fetal mouse palate cultured in vitro. *Anatomy and Embryology* 208, 19-25.
 Cuervo R., Valencia C., Chandraratna R.A.S., Covarrubias L. (2002). Programmed cell death is required for palate shelf fusion and is regulated by retinoic acid. *Developmental Biology* 245, 145-156.
 Dudas M., Li W., Kim H., Yang A., Kaartinen V. (2006). Palatal fusion – Where do the midline cells go? A review on cleft palate, a major human birth defect. *Acta Histochemica* 109, 1-14.
 Elwood J.M., Colquhoun T.A. (1997). Observations on the prevention of cleft palate in dogs by folic acid and potential relevance to humans. *New Zealand Veterinary Journal* 45, 254-256.
 Ferguson M.W.J. (1981). The structure and development of the palate in Alligator mississippiensis. *Archives of Oral Biology* 26, 427-443
 Ferguson M.W.J. (1988). Palate development. *Development* 103 Supplement, 41-60.
 Foreman D.M., Sharpe P.M., Ferguson M.W.J. (1991). Comparative biochemistry of mouse and chick secondary-palate development in vivo and in vitro with particular emphasis on extracellular matrix molecules and the effects of growth factors on their synthesis. *Archives of Oral Biology* 36, 457-471.
 Fraser F.C. (1967). Cleft lip and cleft palate. *Science* 158, 1603-1606.
 Goldman A.S., Baker L., Piddington R., Marx B., Herold R., Egler J. (1985). Hyperglycemia-induced teratogenesis is mediated by a functional deficiency of arachidonic acid. In: *Proceedings of the National Academy of Sciences of the United States of America* 82, 8227-8231.
 Griffith C.M., Hay E.D. (1992). Epithelial-mesenchymal transformation during palatal fusion: carboxyfluorescein traces cells at light and electron microscopic levels. *Development* 116, 1087-1099.
 Griffiths L.G., Sullivan M. (2001). Bilateral overlapping mucosal single-pedicle flaps for correction of soft palate defects. *Journal of the American Animal Hospital Association* 37, 183-186.
 Howard D.R., Davis D.G., Merkley D.F., Krahwinkel D.J., Schirmer R.G., Brinker W.O. (1974). Mucoperiosteal flap technique for cleft palate repair in dogs. *Journal of the American Veterinary Medical Association* 165, 352-354.
 Ingwersen W. (2005). Congenital and inherited anomalies of the digestive system. In: Kahn C.M. (Editor). *The Merck Veterinary Manual*. 9th Edition, Merck & Co., Whitehouse Station N.J., p. 131-137.
 Ishikawa Y., Goris R.C., Nagaoka K. (1994). Use of a cortico-cancellous bone graft in the repair of a cleft palate in a dog. *Veterinary Surgery* 23, 201-205.
 Jin J., Ding J. (2006). Analysis of cell migration, transdifferentiation and apoptosis during mouse secondary palate fusion. *Development* 133, 3341-3347.
 Johnson C.Y., Little J. (2008). Folate intake, markers of folate status and oral clefts: is the evidence convincing? *International Journal of Epidemiology* 37, 1041-1058.

- Kang P., Svoboda K.K.H. (2005). Epithelial-mesenchymal transformation during craniofacial development. *Journal of Dental Research* 84, 678-690.
- Kemp C., Thiele H., Dankof A., Schmidt G., Lauster C., Fernald G., Lauster R. (2009). Cleft lip and/or palate with monogenic autosomal recessive transmission in Pyrenees Shepherd dogs. *Cleft Palate-Craniofacial Journal* 46, 81-88.
- Knott L., Hartridge T., Brown N.L., Mansell J.P., Sandy J.R. (2003). Homocysteine oxidation and apoptosis: a potential cause of cleft palate. *In Vitro Cellular & Developmental Biology*. *Animal* 39, 98-105.
- Krapels I.P.C., Van Rooij I.A.L.M., Ocké M.C., West C.E., Van der Horst C.M.A.M., Steegers-Theunissen R.P.M. (2004). Maternal nutritional status and the risk for orofacial cleft offspring in humans. *The Journal of Nutrition* 134, 3106-3113.
- Krapels I.P., Vermeij-Keers C., Müller M., de Klein A., Steegers-Theunissen R.P.M. (2006). Nutrition and genes in the development of orofacial clefting. *Nutrition Reviews* 64, 280-288.
- Leite I.C.G., Paumgarten F.J.R., Koifman S. (2002). Chemical exposure during pregnancy and oral clefts in newborns. *Cadernos de Saúde Pública* 18, 17-31.
- Lu S., He W., Shi B., Meng T., Li X., Liu Y. (2008). A preliminary study on the teratogenesis of dexamethasone and the preventive effect of vitamin B₁₂ on murine embryonic palatal shelf fusion in vitro. *Journal of Zhejiang University Science B* 9, 306-312.
- Mansell J.P., Kerrigan J., McGill J., Bailey J., Tekoppele J., Sandy J.R. (2000). Temporal changes in collagen composition and metabolism during rodent palatogenesis. *Mechanism of Ageing and Development* 119, 49-62.
- Martinez-Álvarez C., Tudela C., Pérez-Miguelsanz J., O'Kane S., Puerta J., Ferguson M.W.J. (2000). Medial edge epithelial cell fate during palatal fusion. *Developmental Biology* 220, 343-357.
- McGeady T.A., Quinn P.J., FitzPatricj E.S., Ryan M.T. (2006). *Veterinary Embryology*, Blackwell Publishing, Oxford, p. 268-285.
- Morris-Wiman J., Brinkley L. (1993). Rapid changes in the extracellular matrix accompany in vitro palatal shelf remodelling. *Anatomy and Embryology* 188, 75-85.
- Murray J.C., Schutte B.C. (2004). Cleft palate: players, pathways and pursuits. *The Journal of Clinical Investigation* 113, 1676-1678.
- Nelson A.W. (2003). Cleft palate. In: Slatter D. (editor). *Textbook of Small Animal Surgery*. Volume 1, 3th edition, Saunders, p. 814-823.
- Noden D.M., de Lahunta A. (1985). *The Embryology of Domestic Animals, Developmental Mechanisms and Malformations*. Williams & Wilkins, London, p. 172-195.
- Okano J., Suzuki S., Shiota K. (2006). Regional heterogeneity in the developing palate: morphological and molecular evidence for normal and abnormal palatogenesis. *Congenital Anomalies* 46, 49-54.
- Richtsmeier J.T., Sack G.H., Grausz H.M., Cork L.C. (1994). Cleft Palate with Autosomal Recessive Transmission in Brittany Spaniels. *Cleft Palate Craniofacial Journal* 31, 364-371.
- Robertson R.T., Allen H.L., Bokelman D.L. (1979). Aspirin: Teratogenic Evaluation in the Dog. *Teratology* 20, 313-320.
- Sager M., Nefen S. (1998). Use of buccal mucosal flaps for the correction of congenital soft palate defects in three dogs. *Veterinary Surgery* 27, 358-363.
- Sinibaldi K.R. (1979). Cleft palate. *Veterinary Clinics of North America: Small Animal Practice* 9, 245-256.
- Sinowatz F. (1991). Verdauungskanal und Anhangsorgane. In: Rüsse I, Sinowatz F. (editors). *Lehrbuch der Embryologie der Haustiere*. Verlag Paul Parey, Hamburg, p. 338-367.
- Taparia S., Gelineau-van Waes J., Rosenquist T.H., Finnell R.H. (2007). Importance of folate-homocysteine homeostasis during early embryonic development. *Clinical Chemistry and Laboratory Medicine* 45, 1717-1727.
- Thornton J.B., Nimer S., Howard P.S. (1996). The incidence, classification, etiology, and embryology of oral clefts. *Seminars in Orthodontics* 2, 162-168.
- Verhaert L. (2007). Development defects of the jaws. In: Tutt C., Deepprose J., Crossley D. (editors). *BSAVA Manual of Small Animal Dentistry*. 2nd Edition., p. 90-95.
- Warzee C.C., Bellah J.R., Richards D. (2001). Congenital unilateral cleft of the soft palate in six dogs. *Journal of Small Animal Practice* 42, 338-340.
- Weinzweig J., Panter K.E., Patel J., Smith D.M., Spangenberg A., Freeman M.B. (2008). The Fetal Cleft Palate: V. Elucidation of the Mechanism of Palatal Clefting in the Congenital Caprine Model. *Plastic and Reconstructive Surgery* 121, 1328-1334.
- Yoneda T., Pratt R.M. (1982). Vitamin B6 reduces cortisone-induced cleft palate in the mouse. *Teratology* 26, 255-258.
- Young D.L., Schneider R.A., Hu D., Helms J.A. (2000). Genetic and teratogenic approaches to craniofacial development. *Critical Reviews in Oral Biology and Medicine: an Official Publication of the American Association of Oral Biologists* 11, 304-317.